· CASE ANALYSES · · 临床病例讨论 ·

DOI:10.11817/j.issn.1672-7347.2016.06.014
www.csumed.org/xbwk/fileup/PDF/201606637.pdf

Image and pathological features of Ewing's sarcoma in the oral and maxillofacial region

HUANG Lingzhi[1,2], CHEN Xiaofang[3], LI Lezhi[4]

(1. Xiangya Nursing School, Central South University, Changsha 410013; 2. Department of Cardiology, Second Xiangya Hospital, Central South University, Changsha 410011; 3. Nursing Department, Third Affiliated Hospital of Southern Medical University, Guangzhou 510630; 4. Nursing Department, Second Xiangya Hospital, Central South University, Changsha 410011, China)

ABSTRACT

Objective: To systematically evaluate the image and pathological features of Ewing's sarcoma (ES) in the oral and maxillofacial region.

Methods: Eight patients with ES in the oral and maxillofacial region were enrolled for this study. The X-ray, computed tomography (CT), and magnetic resonance imaging (MRI) of ES and the pathological data were systematically evaluated.

Results: X-ray image showed a diffuse radiolucency with cystic component and ill-defined borders for bone lesion. CT showed that there was osteolytic mass with extensive bone destruction and soft tissue infiltration, but no periosteal reactions were observed. MRI demonstrated that ES showed an inhomogeneous structure and blurred borders with invasion to adjacent soft tissue for bone lesion. Similar manifestation also showed in MRI images for patients with soft tissues. Histologically, ES composed of small round cells, and expressed CD99, neuron specific enolase (NSE) and vimentin (Vim) in all patients. Desmin (Des), CD34, epithelial membrane antigen (EMA), chromogranin A (ChgA), etc, were negatively expressed in ES cells.

Conclusion: X-ray, CT, and MRI are helpful to determine the property, extent and the relationship of ES with the surrounding tissues. Immunohistochemical stain of CD99, NSE, and Vim are helpful to confirm the pathological diagnosis of ES.

KEY WORDS image; pathology; Ewing's sarcoma; oral and maxillofacial region

Date of reception: 2015-10-31
First author: HUANG Lingzhi, Email: lingzhihuang99@163.com
Corresponding author: LI Lezhi, Email: xyeyyhlz@sina.com

口腔颌面部尤文肉瘤的影像学和病理学特点

黄伶智[1,2]，陈小芳[3]，李乐之[4]

(1. 中南大学湘雅护理学院，长沙 410013；2. 中南大学湘雅二医院心血管内科，长沙 410011；
3. 南方医科大学第三附属医院护理部，广州 510630；4. 中南大学湘雅二医院护理部，长沙 410011)

[摘要] 目的：系统研究口腔颌面部尤文肉瘤的影像学和病理学特点。**方法：**将8名患有口腔颌面部尤文肉瘤的患者纳入本研究，并系统评价其X线、CT和MRI图像特征及病理学特点。**结果：**X线结果显示颌骨尤文肉瘤表现为弥漫性、透射性的囊性结构，边界不清。CT结果显示颌骨肉瘤表现为骨质广泛性破坏并且有溶骨性病变，同时侵犯软组织，但没有骨膜反应。MRI结果显示颌骨尤文肉瘤组织的信号不均匀，边界不清楚同时侵犯相邻的软组织。软组织尤文肉瘤的MRI图像与颌骨尤文肉瘤的MRI表现相似。组织学结果显示尤文肉瘤由小圆细胞组成，并表达CD99、神经元特异性烯醇化酶(NSE)和波形蛋白 (Vimentin)，不表达Des，CD34，上皮膜抗原(epithelial membrane antigen， EMA)和嗜铬粒蛋白A(chromogranin A，ChgA)等标志物。**结论：**X线、CT及MRI有助于确定尤文肉瘤的性质、与周围组织的关系及侵犯程度。CD99，NSE和Vimentin免疫组织化学染色有助于尤文肉瘤的病理诊断。

[关键词] 影像；病理；尤文肉瘤；口腔颌面部

Ewing's sarcoma (ES) was firstly reported by James Ewing in 1921[1]. ES is a rare, highly malignant tumor that occurs most often in and around the bones, and comprises about 4% to 6% of all primary bone tumors. Only 2%–7% patients are involved in the oral and maxillofacial region in ES, and the mandible and temple are the most frequent sites[2-3]. Most of cases occur in children and young adult, and males are more often affected than females[3]. ES's clinical symptoms mainly include swelling, pain and sensory disturbances that are rather unspecific[3]. Thus the diagnosis based on clinical findings is still a challenge. The appropriate treatment for ES was complete surgical excision of the tumor associated with radiotherapy and chemotherapy, and the most important indicator is the primary site, thus, primary tumors in the oral and maxillofacial region have a significantly higher survival ratio[3-4]. All of above features suggested that precise diagnosis for ES in the oral and maxillofacial region is urgent necessary.

The general radiologic appearance of ES was a mass accompanied by bone destruction, and the "sun ray" lesion is a common finding[5-6]. However, a systematic analysis of X-Ray, CT, and MRI images for ES in the oral and maxillofacial region has not been reported. ES is a poorly differentiated tumor with small, round and blue cells[7-8]. Primitive neural crest cells, embryonic osteochondrogenic progenitors, hematopoietic cells, and muscle cells as well as mesenchymal stem cells have been considered possible cells of ES origin[9-10], and definite pathological diagnosis for ES was mainly based on immunohistochemical staining for many markers now. Unfortunately, pathological diagnosis for ES in the oral and maxillofacial region has not been detailedly described[8-11]. In this study, we tried to systematically analyze the image and pathological features of ES in the oral and maxillofacial region to better understand the disease.

1 Patients and Methods

1.1 Patients

Patients with oral and maxillofacial disease registered in our hospital were reviewed to retrieve relevant information about patients with ES in oral and maxillofacial region during the past 10 years (2003–2013). Inclusion criteria were the patients with detailed data including definitive diagnosis based on clinical manifestations, radiographic and pathological findings. The medical records of these enrolled patients were subjected to further review to get these information regarding patient demographics, radiological, and clinical pathological data. Finally, 8 patients, 7 females and 1 male were included in this study, and the basic information of these patients was showed in Table 1. This retrospective study was performed in accordance with guidelines of the CONSORT, and was approved by Ethics Committee in the Second Xiangya Hospital, Central South University, China.

1.2 Image analysis

The X-ray, CT, and MRI data of these patients were obtained from the Department of Radiology, and were

stored in digital imaging and communications in medicine (DICOM) format to be imported into the special software to read it. The radiological features of ES, including the margin, invasion, density or signal intensity, were reviewed and recorded by a radiologist and an oral and maxillofacial surgeon to find out the common radiological appearance of ES in the oral and maxillofacial region.

1.3 Pathological analysis

The primitive pathological sections of these patients were collected from Department of Radiology, and were observed under microscope. The pathological features of ES in the oral and maxillofacial region, including margin, structure and cell morphology, were observed and recorded by an experienced pathologist. For immunohistochemical staining, 3 sections and 10 high power field (HPF) in each section were randomly selected to analyze the proportion of positive cells per HPF.

2 Results

2.1 Clinical information

Of the 8 patients (female:male=7:1), the age was 11 to 48(23.88±7.38) years old. The lesion was existed in facial soft tissues of 2 patients, 2 in maxilla and 4 in mandible. The detailed information for the 8 patients was showed in Table 1.

Table 1 Patients' information and pathological findings

Cases	Gender	Age/ (years old)	Location of the disease	Pathological findings
1	Female	48	Chin (soft tissue)	Positive: Vim, NSE, CD99, Syn
				Negative:L26, CD3, CD43, CKP, CD79a, EMA, ChgA, Des, MyoD1, CD56
2	Male	18	Maxilla	Positive: Vim, CD99, NSE, MBP, CD57, syn, Ki-67(41%)
				Negative: LCA, S-100, CD3, EMA, MPO, GFAP, ChgA, EMA
				PAS staining: A small amount positive
3	Female	19	Mandible	Positive: NSE, Syn, CD99, Vim, Calp, SMA, Des
				Weak positive: CK7, EMA, CK19, Bcl-2, S-100
				Negative: SMA, CD34, CKP, CD57, GFAP, ChgA, MBP, Caldesmon
				PAS staining: positive
4	Female	22	Cheek (soft tissue)	Positive:Vim, CD99, NSE, Syn
				Negative:LCA, MPO, Des, SMA, CD34, CD57, ChgA, EMA, S-100, CKP
				PAS staining: negative
5	Female	20	Maxilla	Positive: NSE, CD99, Syn, S-100, Vim, Ki-67(10%)
				Negative: ChgA
6	Female	17	Mandible	Positive: Vim, CD99, NSE, Syn, Ki-67(20%)
				Weak positive: S-100
				Negative: MPO, EMA, CD57, ChgA, S-100, Des, LCA, CD34
7	Female	11	Mandible	Positive: Vim, CD99, F8
				Negative: MyoD1, Syn, NSE, CD31, CD34, S-100, SMA, CKP, EMA, Des
8	Female	36	Mandible	Positive: CD99, Vim, NSE, Bcl-2, CD57
				Negative: CKP, EMA, S-100, ChgA, Des, CKH, CD34
				PAS staining: positive

Vim: Vimentin; NSE: Neuron specific enolase; ChgA: Chromogranin A; Bcl-2: B-cell lymphoma-2; Calp: Calpain; CKH: Cytokeratin high molecular weight; CKP: Pan-cytokeratin; GFAP: Glial fibrillary acidic portein; EMA: Epithelial membrane antigen; LCA: CD45; MBP: Myelin basic protein; MPO: Myeloperoxidase; MyoD1: Myogenic differentiation 1; SMA: Smooth muscle actin

2.2 Radiological features of ES in the oral and maxillofacial region

A panoramic radiograph was taken for patients with bone lesion, and showed a diffuse radiolucency with cystic component and ill-defined borders. Additionally, there was cortical destruction and bone expansion both in maxilla

and mandible (Figure 1).

CT examination was performed in patients with bone lesion, and showed that there was osteolytic lesion with extensive bone destruction and soft tissue infiltration in all the 6 patients with jaw Ewing's sarcoma, and resulted in cortical thinning with discontinuity of the cortex at multiple sites. The lesion exhibited heterogeneous matrix with slightly higher density when compared to surrounding soft tissues, as well as exhibited blurred borders with surrounding tissues (Figure 2). No periosteal reactions were observed in all the 6 patients with jaw ES, but there was ectopic bone fragments among the 2 maxillary tumors, and these bone fragments mainly existed in the margin region of the lesion (2/2). However, no osteogenic lesion exists in the 8 patients.

MRI examinations for patients with bone lesion (6/6) demonstrated that ES showed an inhomogeneous structure and blurred borders (Figure 3). It mainly exhibited isointensity signal in T1WI image, uneven enhancement signal in contrast enhanced T1WI image, and high signal in T2WI images. MRI image clearly showed that ES existed in both the marrow and cortex of bone, and caused bone thinning and cortex discontinuation with invasion to adjacent soft tissues (Figure 4). Similar manifestation also showed in MRI images for patients with soft tissues (2/2), and the lesion showed heterogeneously enhanced signal contrast enhanced T1-weighted images, whereas enhanced signal was revealed in T2-weighted image with fat saturation (Figure 4).

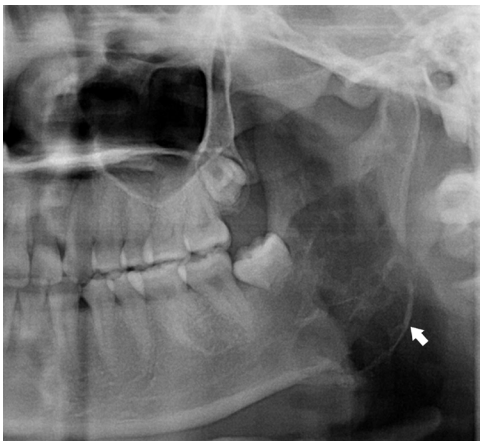

Figure 1 Panoramic radiography for a patient with mandibular ES (arrow)

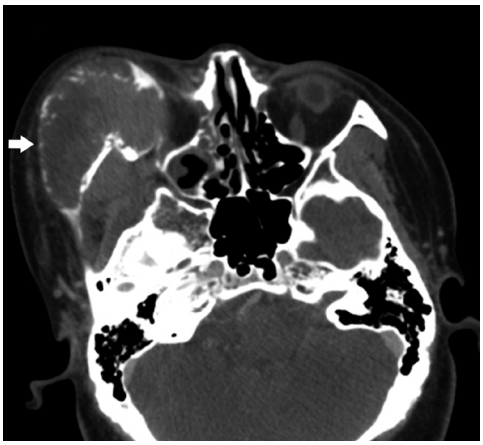

Figure 2 CT for a patient with maxillary ES (arrow)

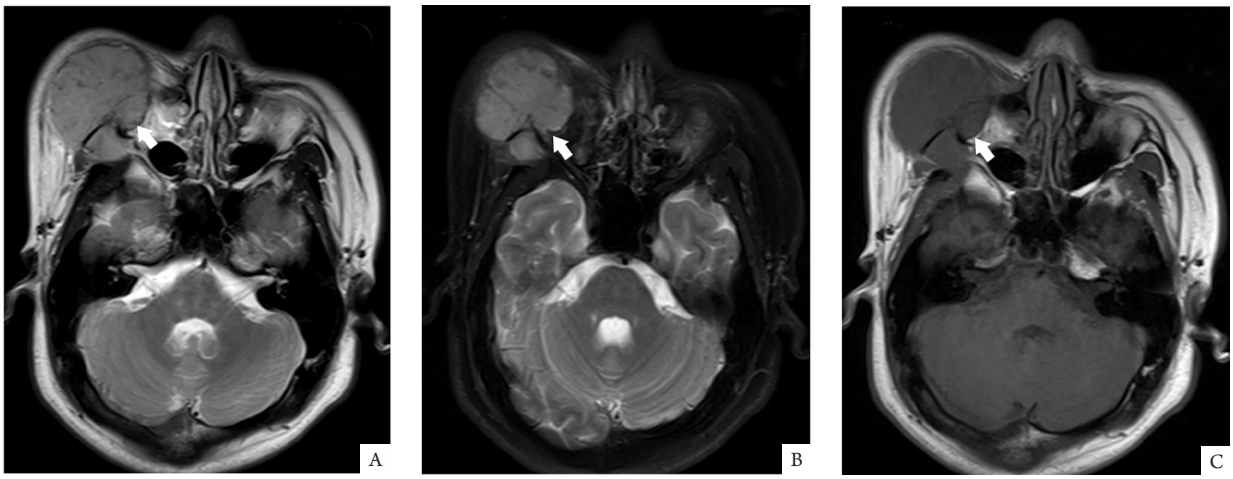

Figure 3 MRI for a patient with maxillary ES (arrows)

A: Contrast enhanced T1-weighted images; B: T2-weighted image with fat saturation; C: T1-weighted images

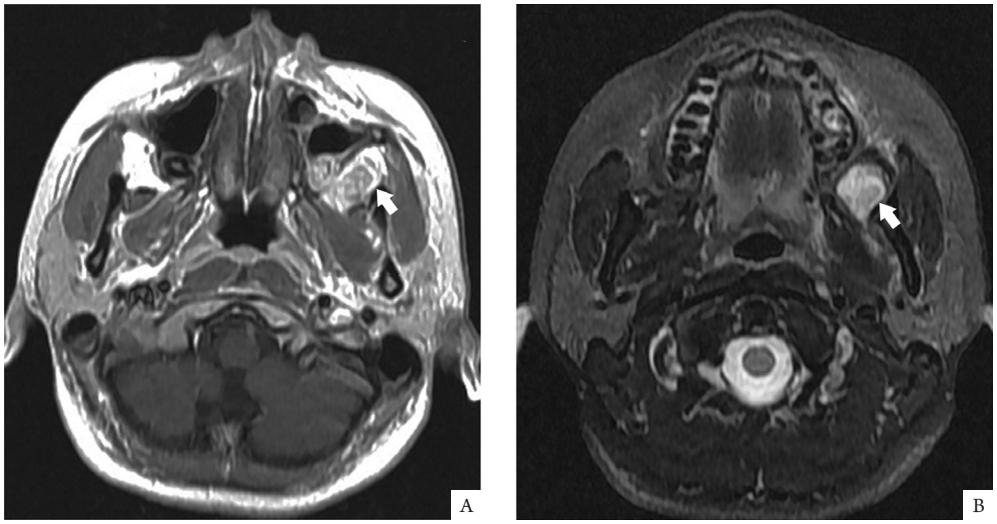

Figure 4 MRI for a patient with cheek ES (arrows)

A: Contrast enhanced T1-weighted images; B: T2-weighted image with fat saturation

2.3 Pathological features of ES in the oral and maxillofacial region

Histologically, ES was composed of uniform small round cells with scant cytoplasm (high nuclear to cytoplasmic ratio), round nuclei with finely dispersed chromatin, and one or more tiny nucleoli. The cytoplasm was eosinophilic. Three patients (3/5) with jaw Ewing's sarcoma contained glycogen detected by periodic acid Schiff (PAS) stain. However, the PAS staining was negative in a patient (1/2) with soft tissues lesion. Besides, Rosette formation could be observed.

CD99, neuronspecific enolase (NSE), and vimentin (Vim) were expressed in ES cells of 8 patients. The tumor cells also expressed NSE and synaptophysin (Syn) in 6 patients (6/8), as well as Ki-67 in 3 patients (3/8). However, S-100 protein was weakly expressed in 3 patients with jaw lesion (3/6). Des, CD34, EMA, ChgA, etc were negatively expressed in tumor cells (Table 1).

3 Discussion

ES rarely originate in the maxillofacial region, usually involving the mandible[3,12]. Our observation showed that 5 patients had mandible lesion. Previous study[12-13] revealed that 90% ES occurs in the first 3 decades of life and males are more often affected than females. Our study demonstrated that 6 out of 8 patients were young people, and 7 out of 8 patients were female.

An X-ray examination is essential in the diagnostics of jaw Ewing's sarcoma[5]. X-ray could effectively reveal a mass and bone destruction in jaw. However, X-ray sometimes could not confirm a benign or malignant tumor. Thus, CT is a supplementary examination and is useful to evaluate bone destruction, especially the lesions of jaws where the periosteal reactions may be absent or limited, and soft tissue invasion[5-6,14-15]. ES showed isointensity signal in T1WI MRI image, uneven enhancement signal in contrast enhanced T1WI image, and high signal in T2WI images. MRI allows for a detailed evaluation for tumor borders and soft tissue involvement. Previous studies[16-17] showed that ES in long bone may develop along the long axis, and periosteal reactions are usually observed. However, no periosteal reactions were observed in flat bone (including jaw bone). Periosteal reactions may happen in different structures and blood supply for flat bones. In addition, compared to ill-defined borders in jaw ES, there was relative clear borders in soft tissues of ES. CT is also useful in diagnosing whether the tumor is a benign or malignant tumor, and benefits to determine the lesion border during the treatment-planning process[16-17].

Diagnosis of ES requires a pathological confirmation. ES was composed of typical small round cells[18]. Based on histology, immunostains, and electron microscope. Previous studie[7] postulated that ES is a primitive mesenchymal neoplasm with the potential for multidirectional differentiation. Many markers, such

as CD99, friend leukemia integration 1 (FLI1), and caveolin1 (CAV1), are commonly expressed in ES and are used to differentiate them from other small round cell tumors[7,11,19]. Additionally, markers of neural, epithelial, and mesenchymal differentiation have also been described in various sub-types of ES[7,11]. Similarly, our result revealed that ES cells in the oral and maxillofacial region expressed CD99, NSE, and Vim in all the 8 patients, suggesting that CD99, NSE, and Vim are useful to diagnose the ES in the oral and maxillofacial region. In addition, Des, CD34, EMA, ChgA negatively expressed in ES cells in the oral and maxillofacial region. It implies that these markers may be useful to exclude other tumors from ES in the oral and maxillofacial region.

The histological examination showed sheets of pleomorphic round cells and a poorly defined cellular boundary. Moreover, thin connective tissue septa with capillaries were seen between sheets, suggesting a malignant tumor, and the histopathological characteristics were consist with imaging manifestations (heterogeneously signal and density, and blurred lesion borders).

In summary, this study revealed that ES in the oral and maxillofacial region mainly involved mandible in young female patients. To confirmly diagnose ES, all clinical, radiological, histopathological and immunohistochemistry features are necessary. An X-ray examination is recommended in the diagnostics of jaw ES, and CT can be performed as a supplementary examination to evaluate bone destruction, periosteal reactions, and soft tissue invasion. MRI is helpful to determine the lesion border during the treatment-planning process. CD99, NSE, and Vim may be useful to confirm the diagnosis of ES in the oral and maxillofacial region.

Conflict of interest

The authors declare no conflict of interest.

Acknowledgements

The study was supported by the Department of Pathology, The Second Xiangya Hospital of Central South University, China.

References

[1] Tanaka M, Yamazaki Y, Kanno Y, et al. Ewing's sarcoma precursors are highly enriched in embryonic osteochondrogenic progenitors[J]. J Clin Invest, 2014, 124(7): 3061-3074.

[2] Talesh KT, Motamedi MH, Jeihounian M. Ewing's sarcoma of the mandibular condyle: report of a case [J]. J Oral Maxillofac Surg, 2003, 61(10): 1216-1219.

[3] Gosau M, Baumhoer D, Ihrler S, et al. Ewing sarcoma of the mandible mimicking an odontogenic abscess— a case report[J]. Head Face Med, 2008, 4: 24.

[4] Allam A, El-Husseiny G, Khafaga Y, et al. Ewing's sarcoma of the head and neck: a retrospective analysis of 24 cases[J]. Sarcoma, 1999, 3(1): 11-15.

[5] Kuleta-Bosak E, Kluczewska E, Machnik-Broncel J, et al. Suitability of imaging methods (X-ray, CT, MRI) in the diagnostics of Ewing's sarcoma in children-analysis of own material[J]. Pol J Radiol, 2010, 75(1): 18-28.

[6] Li WY, Brock P, Saunders DE. Imaging characteristics of primary cranial Ewing sarcoma[J]. Pediatr Radiol, 2005, 35(6): 612-618.

[7] Desai SS, Jambhekar NA. Pathology of Ewing's sarcoma/PNET: Current opinion and emerging concepts[J]. Indian J Orthor, 2010, 44(4): 363-368.

[8] Pinto A, Dickman P, Parham D. Pathobiologic markers of the ewing sarcoma family of tumors: state of the art and prediction of behaviour[J]. Sarcoma, 2011, 2011: 856190.

[9] Hu-Lieskovan S, Zhang J, Wu L, et al. EWS-FLI1 fusion protein up-regulates critical genes in neural crest development and is responsible for the observed phenotype of Ewing's family of tumors[J]. Cancer Res, 2005, 65(11): 4633-4644.

[10] Tirode F, Laud-Duval K, Prieur A, et al. Mesenchymal stem cell features of Ewing tumors[J]. Cancer Cell, 2007, 11(5): 421-429.

[11] Llombart-Bosch A, Navarro S. Immunohistochemical detection of EWS and FLI-1 proteinss in Ewing sarcoma and primitive neuroectodermal tumors: comparative analysis with CD99 (MIC-2) expression[J]. Appl Immunohistochem Mol Morphol, 2001, 9(3): 255-260.

[12] Bonet J, Minguez JM, Penarrocha M, et al. Ewing s sarcoma of the mandible. A case report[J]. Med Oral, 2000, 5(4): 279-282.

[13] Ko E, Brouns ER, Korones DN, et al. Primary Ewing sarcoma of the anterior mandible localized to the midline[J]. Oral Surg Oral Med Oral Pathol Oral Radiol, 2013, 115(6): e46-50.

[14] Zhang WD, Zhao LL, Huang XB, et al. Computed tomography imaging of anterior and middle mediastinal Ewing sarcoma/primitive neuroectodermal tumors[J]. J Thorac Imaging, 2010, 25(2): 168-172.

[15] Avcu S, Ozcan HN, Izmirli M, et al. CT and MR findings in a neuroforaminal extraskeletal Ewing sarcoma mimicking benign nerve sheath tumor[J]. Ir J Med Sci, 2012, 181(1): 123-125.

[16] Frouge C, Vanel D, Coffre C, et al. The role of magnetic resonance imaging in the evaluation of Ewing sarcoma. A report of 27 cases[J]. Skeletal Radiol, 1988, 17(6): 387-392.

[17] Kauffman WM, Fletcher BD, Hanna SL, et al. MR imaging findings in recurrent primary osseous Ewing sarcoma[J]. Magn Reson Imaging, 1994, 12(8): 1147-1153.

[18] Risi E, Iacovelli R, Altavilla A, et al. Clinical and pathological features

of primary neuroectodermal tumor/Ewing sarcoma of the kidney[J]. Urology, 2013, 82(2): 382-386.

[19] Folpe AL, Hill CE, Parham DM, et al. Immunohistochemical detection of FLI-1 protein expression: a study of 132 round cell tumors with emphasis on CD99-positive mimics of Ewing's sarcoma/primitive neuroectodermal tumor[J]. Am J Surg Pathol, 2000, 24(12): 1657-1662.

(Edited by CHEN Liwen)

本文引用：黄伶智，陈小芳，李乐之. 口腔颌面部尤文肉瘤的影像学和病理学特点[J]. 中南大学学报：医学版，2016, 41(6): 637-643. DOI:10.11817/j.issn.1672-7347.2016.06.014

Cite this article as: HUANG Lingzhi, CHEN Xiaofang, LI Lezhi. Image and pathological features of Ewing's sarcoma in the oral and maxillofacial region[J]. Journal of Central South University. Medical Science, 2016, 41(6): 637-643. DOI:10.11817/j.issn.1672-7347.2016.06.014

领跑者 5000——中国精品科技期刊顶尖学术论文平台 (F5000)

为了进一步推动我国科技期刊的发展，提高其整体水平，更好地宣传和利用我国的优秀学术成果，起到引领和示范的作用。中国科学技术信息研究所（中信所）在中国精品科技期刊中遴选优秀学术论文，建立了“领跑者 5000——中国精品科技期刊顶尖学术论文平台 (F5000)”，集中对外展示和交流我国的优秀学术论文。

在《中国科技论文与引文数据库 (CSTPCD)》的基础上，计算每篇论文在 2010—2014 年 5 年时间窗口内累计被引用的次数。强化单篇论文定量评估方法的研究和实践。采用定量分析和定性分析相结合的方法，对学术期刊的质量和影响力作了进一步的科学评价，遴选新的精品科技期刊，并从每种精品期刊中择优选取了 2010—2014 年期间发表的最多 20 篇学术论文作为 F5000 的提名论文。

中信所与汤森路透集团达成了合作意向，汤森路透提供 F5000 论文被 SCI 论文引用的数据链接，经过汤森路透中国公司与美国总部技术人员的多次协调，目前这一工作已基本实现，F5000 平台实现 2 个月更新一次被引次数，并提供 F5000 论文在 *Web of Science* 中引用链接。*Web of Science* 在 2013 年提供 F5000 论文的被引次数和引用链接以来，F5000 论文的被引次数显著增长。未来，F5000 将进入汤森路透的 Incites 评价数据库系统平台，成为 *Web of Science* 的一部分。

中信所与爱思唯尔合作建立了“F5000 和 Mendeley 学者俱乐部”，开展对入选学者俱乐部的研究人员的推荐、管理、培训等活动，向国际同行展示中国在世界科研领域居于领先地位的研究成果和科学家，为我国优秀学者营造国际高端学术交流环境，

中信所将与日本 JST 在 F5000 项目方面进行合作，实现 F5000 论文信息、引文信息与 JST 旗下 J-stage 中日文论文信息、引文信息互换与共享。旨在深化中日两国科技合作，深入了解双方顶尖科研成果的相互影响状态和趋势。

中信所向约翰威立国际出版公司推荐 F5000 的作者，作为其期刊评审专家或期刊编委会成员，面向第一批推荐作者的专家培训会已在 2013 年 11 月份召开，并颁发了证书，今后将继续举办推荐专家培训会。