· CASE ANALYSES · · 临床病例讨论 ·

DOI:10.11817/j.issn.1672-7347.2015.04.018
www.csumed.org/xbwk/fileup/PDF/201504446.pdf

开颅手术后轴外脑脊液蓄积的治疗体会

赵杰，刘景平，张治平，李建，肖格磊，廖新斌，金晨

（中南大学湘雅医院小儿神经外科，中南大学湘雅医院脑积水诊疗中心，长沙 410078）

[摘要] **目的：**回顾性调查轴外脑脊液蓄积在开颅手术后的发生情况及治疗经过，并探讨其病理生理学机制与治疗方法。**方法：**选取46例经纵裂胼胝体入路的开颅手术治疗患者，对其治疗过程进行回顾性分析。**结果：**术后6 h内，CT复查该46例手术患者均出现轴外脑脊液蓄积。经观察与治疗后，5例发展为症状性轴外脑脊液蓄积，并进行了手术治疗。1例院外死亡，1例行硬膜下-腹腔分流，3例先行硬膜下-腹腔分流后改为脑室-腹腔分流。**结论：**开颅手术后经头部CT发现可疑轴外脑脊液蓄积者，应注意跟踪观察及时发现症状性轴外脑脊液蓄积。脑室-腹腔分流术与硬膜下-腹腔分流术是有效的治疗措施。

[关键词] 开颅手术；并发症；术后轴外脑脊液蓄积；硬膜下-腹腔分流术；脑室-腹腔分流术；脑外积水

Experience of treatment for accumulation of extra-axil cerebrospinal fluid after skull surgery

ZHAO Jie, LIU Jingping, ZHANG Zhiping, LI Jian, XIAO Gelei, LIAO Xinbin, JIN Chen

(Division of Pediatric Neurosurgery, Center for Hydrocephalus Diagnosis and Treatment, Xiangya Hospital, Central South University, Changsha 410078, China)

ABSTRACT

Objective: To explore the treatment and pathophysiology of extra-axil cerebrospinal fluid accumulation after skull surgery.

Methods: The treatment of 46 cases of pineal regional tumor was retrospectively studied.

Results: The CT showed that all patients had postoperative extra-axil cerebrospinal fluid accumulation in 6 hours after operation. 5 cases displayed symptomatic accumulation of extra-axil cerebrospinal fluid. 1 died 30 days after discharge, 4 performed S-P shunt and 3 of them switched to V-P shunt after S-P shunt failed.

Conclusion: Much more attention should be paid to postoperative accumulation of extra-axil cerebrospinal fluid. Both V-P and S-P are the effective strategies of therapy.

收稿日期(**Date of reception**)：2014-09-24
第一作者(**First author**)：赵杰，Email: steelzj@126.com
通信作者(**Corresponding author**)：刘景平，Email: liujp5779@Yahoo.com.cn

KEY WORDS craniotomy; complication; postoperative extra-axil cerebrospinal fluid accumulation; subduro-peritoneal shunt; ventriculo-peritoneal shunt; external hydrocephalus

开颅术后轴外脑脊液蓄积是一种手术入路相关并发症，可见于多种涉及脑室及脑基底池开放的手术入路，多数患者为自限性过程，少数患者病情持续进展，如果处理不当可导致灾难性后果。Eguchi等[1]报道了3例病例，并对其形成机制进行了探讨。2011年1月至2014年9月本治疗组采用经纵裂-胼胝体-脉络膜裂入路对46例松果体区(包括松果体区、三脑室中后部及丘脑)病变患者行开颅手术，有5例患者因出现术后轴外脑脊液蓄积行手术治疗，现将其治疗经过报告如下。

1 病例资料

病例1，男，14岁，因头痛伴右侧肢体乏力1月入院。术前影像学资料见图1A。手术采用经纵裂胼胝体入路，病理学检查为星型胶质细胞瘤3级。予以显微镜下全切除，并证实中脑导水管通畅。术后7 d出院。出院后7 d行放射治疗，当日发现头皮下积液予以穿刺。第14天患者出现头痛、呕吐等颅高压症状，并逐渐明显，予以脱水降颅压治疗5 d后患者突发意识障碍，呼之不能应答，随即反复抽搐。头部CT显示双侧轴外脑脊液蓄积(图1B)。紧急行双侧硬膜下穿刺，放出黄色脑脊液约40 mL后，患者意识恢复，回答问题正确。遂急诊行双侧硬膜下外引流术。4 d后试行硬膜下引流管夹闭，复查头部CT显示双侧轴外脑脊液蓄积较前增多(图1C)，拟转我科行分流手术。当晚出现病情变化死亡。

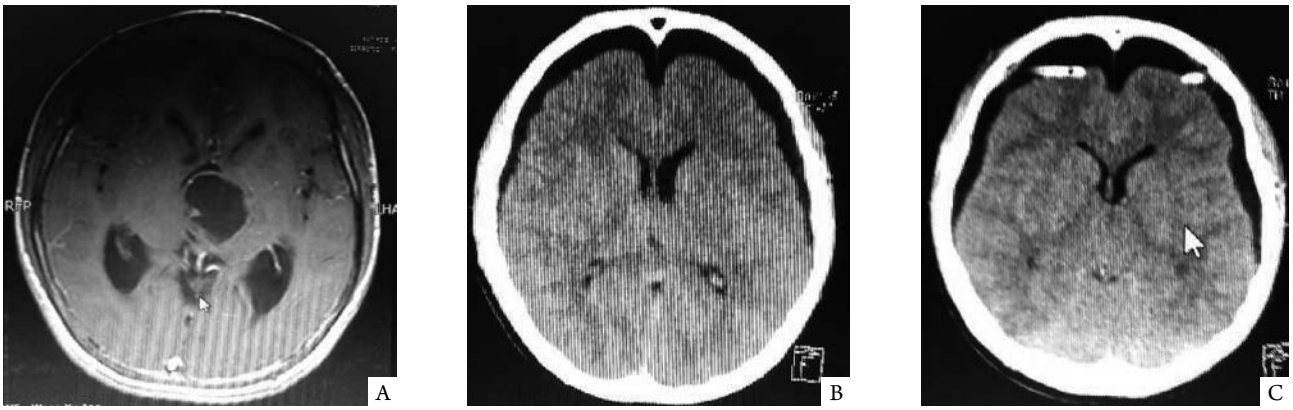

图1　1例星型细胞胶质瘤3级的14岁男性患者的影像资料

Figure 1　Image from a 14-year-old boy with astrocytoma WHO 3

A: MRI before operation; B: CT showed bilateral extra-axil cerebrospinal fluid collection 30 days after operation; C: Subdural drainage was performed

病例2，男，8岁，因双下肢乏力1年，加重伴视力下降2月入院。术前影像学资料见图2A。手术采用经纵裂胼胝体入路，病理学检查为星型胶质细胞瘤2级。予以显微镜下次全切除，并打通中脑导水管。术毕放置右侧脑室外引流管。术后第6天拔除外引流管。拔除外引流5 d后出现意识障碍，头部CT检查发现双侧轴外脑脊液蓄积，行双侧硬膜下外引流术，外引流后左侧基本消失，右侧轴外脑脊液蓄积增加(图2B)。外引流期间多次试夹闭外引流管不能耐受。硬膜下外引流手术7 d后行右侧硬膜下-腹腔分流术，术后意识恢复，轴外脑脊液蓄积明显减少。22 d后患者再次出现意识障碍，证实为分流管硬膜下段梗阻后(图2C)，改行脑室-腹腔分流手术，术后意识恢复(图2D)。

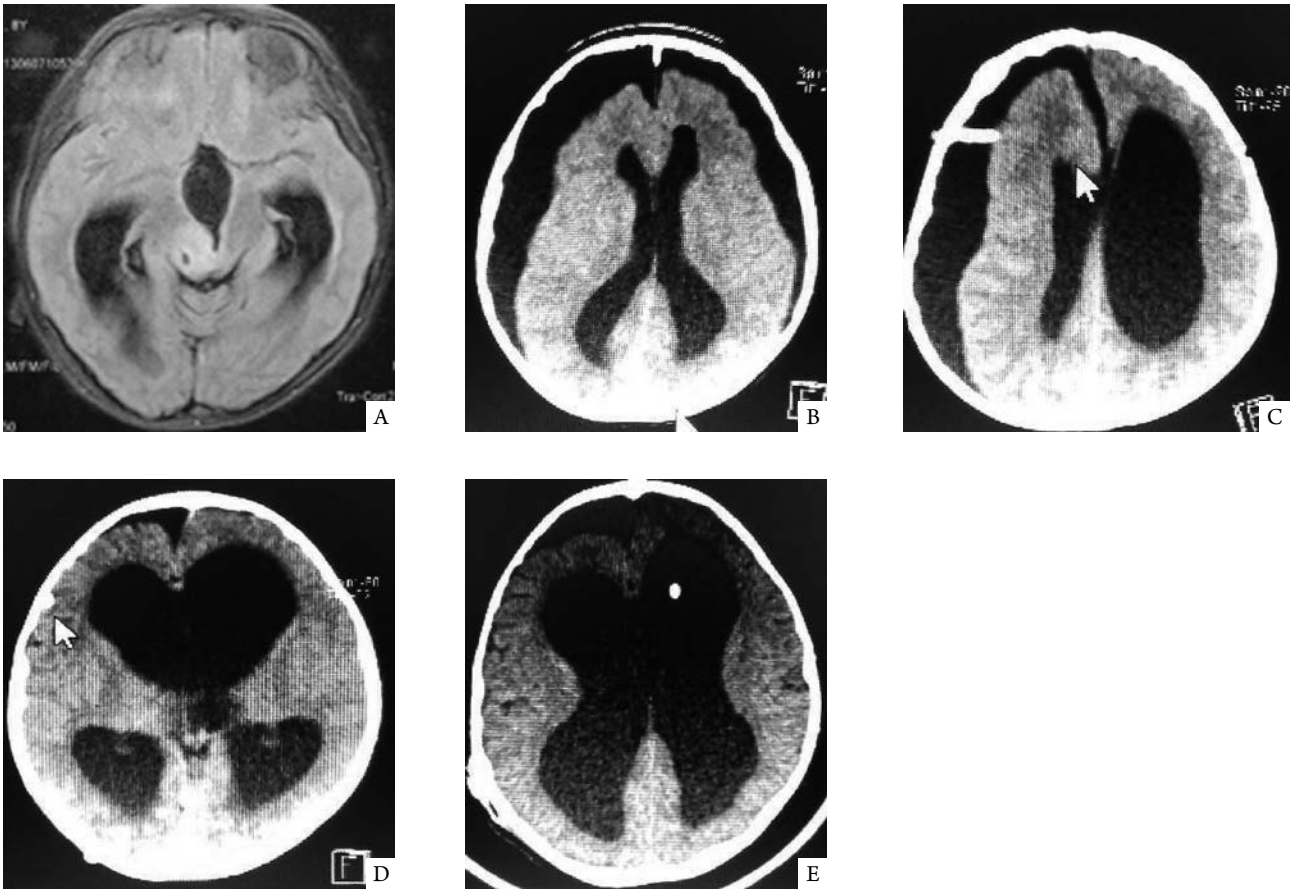

图2 1例星型细胞胶质瘤2级的8岁男性患者的影像资料

Figure 2 Image from a 8-year-old boy with astrocytoma WHO 2

A: MRI before operation; B: Extra-axil cerebrospinal fluid collection 11 days after operation; C: After drainage only the right side remained; D: Subduro-peritoneal shunt failed; E: Ventriculo-peritonilshunt was performed

病例3，女，57岁，因头晕1月，加重伴恶心呕吐2 d入院。术前影像学资料见图3A。入院当日发生脑危象，行侧脑室外引流术，术后意识恢复。住院期间松果体区病变发生出血，再次出现意识障碍。持续脑室外引流患者意识无好转，行开颅手术。手术采用经纵裂胼胝体入路，病理学检查为松果体细胞瘤。予以显微镜下全切除，并打通中脑导水管。术后意识逐渐恢复。33 d后再次意识障碍，头部CT检查发现右侧轴外脑脊液蓄积，予以硬膜下穿刺外引流(图3B)。术后意识再次好转。10 d后行硬膜下-腹腔分流手术。分流手术后4 d再次出现意识障碍，头部CT检查显示轴外脑脊液蓄积减少(图3C)。考虑分流不足或分流管梗阻，改行侧脑室-心房分流术。术后意识恢复(图3D)。

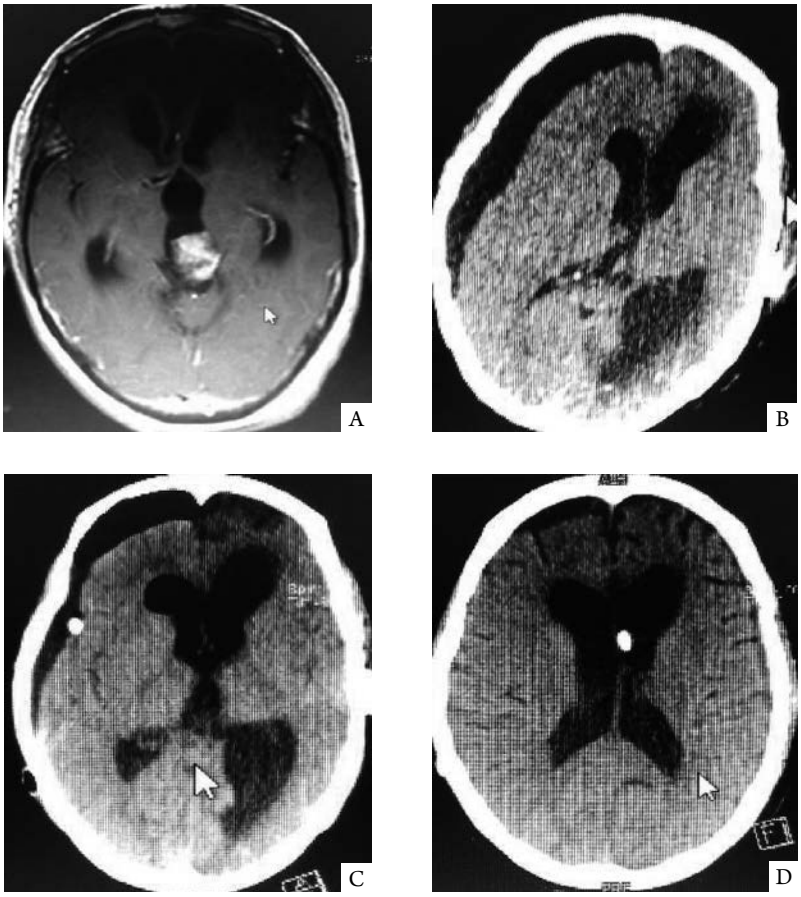

图3　1例松果体细胞瘤的57岁女性患者的影像资料

Figure 3　Image from a 57-year-old female patient with pinealocytoma

A: MRI before operation; B: Left extra-axil cerebrospinal fluid collection; C: Subduro-peritoneal shunt failed; D: Ventriculo-peritoneaalshunt was performed

病例4，男，21岁，因头痛、视物模糊2月，加重伴走路不稳2周入院。术前影像学资料见图4A。手术采用经纵裂胼胝体入路，病理学检查为生殖细胞瘤。予以显微镜下全切除，并打通中脑导水管。术毕放置右侧脑室外引流管。5 d后拔除外引流管。4 d后出现意识障碍，头部CT检查发现双侧轴外脑脊液蓄积，左侧为甚(图4B)。行左侧硬膜下穿刺外引流后意识恢复。拔除外引流期间，患者因意识障碍出现吸入性肺炎。1 d后拔除外引流，4 d后再次出现意识障碍，行硬膜下-腹腔分流手术，意识恢复(图4C)。2 d后再次出现意识障碍，考虑分流不足或分流管梗阻，改行脑室-腹腔分流术，术后意识恢复(图4D)。因分流过度体外调压(图4E)。

病例5，男，23岁，因头晕3月入院。术前影像学资料见图5A。手术采用经纵裂胼胝体入路，病理学检查为生殖细胞瘤。予以显微镜下全切除，并打通中脑导水管。术毕放置右侧脑室外引流管。7 d后拔除外引流管。拔除引流管6 d后患者出现意识障碍，行头部CT发现右侧轴外脑脊液蓄积(图5B)。急诊行右侧硬膜下穿刺外引流术，术后意识恢复。外引流4 d后拔除右侧硬膜下引流管。2 d后患者再次出现意识障碍，急诊行硬膜下-腹腔分流手术，术后意识恢复(图5C)。

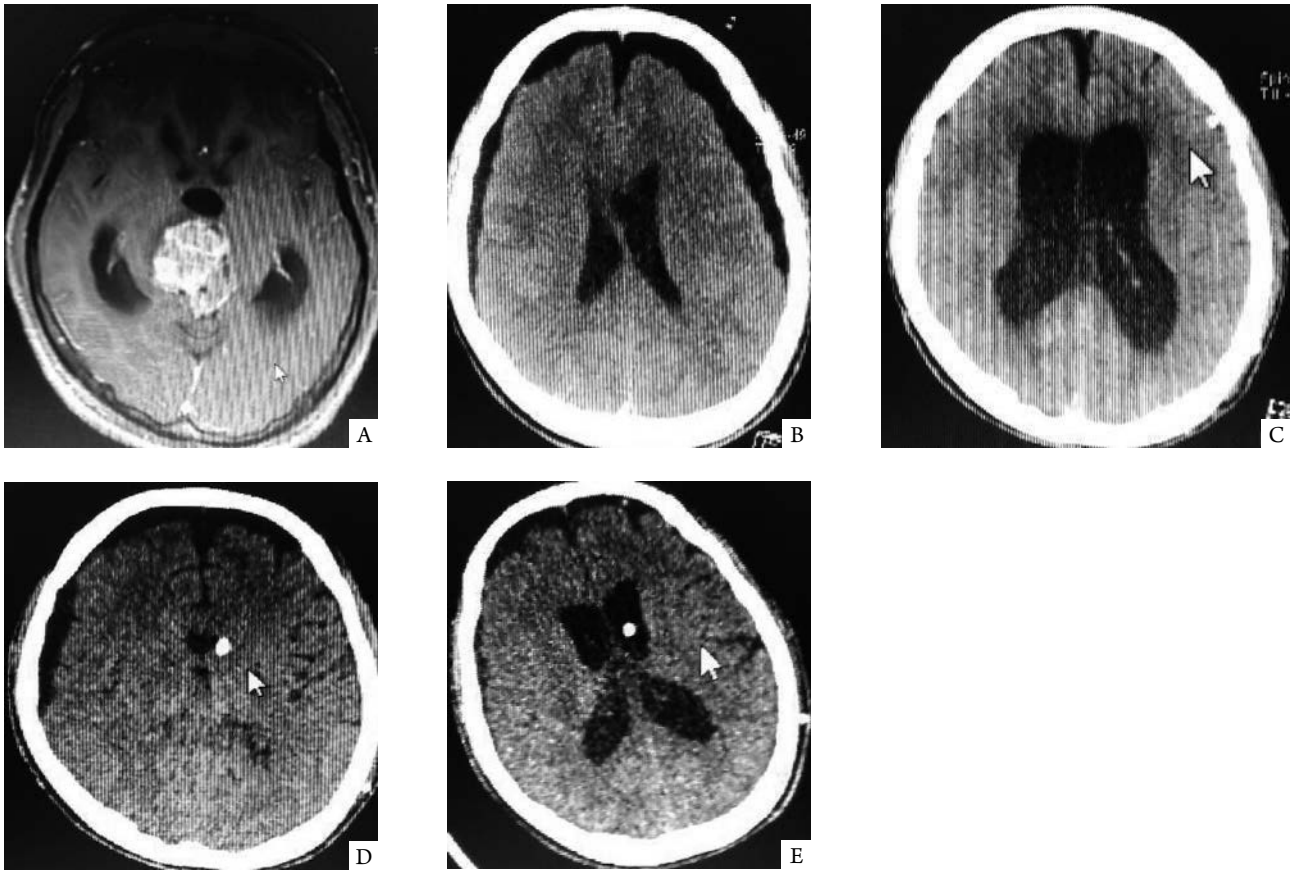

图4 1例生殖细胞瘤的21岁男性患者的影像资料

Figure 4 Image from a 21-year-old male patient with Germinoa

A: MRI before operation; B: Extra-axil cerebrospinal fluid collection 11 days after operation; C: Subduro-peritoneal shunt failed; D: Overdrainage after ventriculo-peritoneal shunt was performed; E: The shunt was readjusted

图5 1例生殖细胞瘤的23岁男性患者的影像资料

Figure 5 Image from a 23-year-old male patient with Germinoa

A: MRI before operation; B: CT show right extra-axil cerebrospinal fluid collection; C: Subduro-peritoneal shunt was performed

2 讨 论

开颅术后轴外脑脊液蓄积与脑外积水同是轴外脑脊液蓄积，有着相似的影像学表现。但两者形成机制可能不同。脑外积水在小儿与成人也有不同的成因。目前认为小儿脑外积水是由于脑脊液吸收障碍所致，脑脊液在蛛网膜下腔蓄积，并使该间隙增大[2-8]。而成人脑外积水即硬膜下水瘤是由于脑脊液的单向循环障碍所致[9-12]。由于对这一大类疾病的形成机制仍不十分清楚，因此对其一直缺乏统一的分类与规范的命名。

Eguchi等[1]认为开颅术后轴外脑脊液蓄积是单独的一种疾病类型，其形成机制与脑外积水不同。在其报道的3例患者中，手术采用经前纵裂-终板入路或经外侧裂-终板入路。两种入路都对蛛网膜进行了广泛的分离，并开放了脑室，使得脑室腔与基底池-硬膜下腔之间建立了新的交通通道，脑脊液因此进入轴外间隙蓄积。这是形成该疾病的最主要的原因。除此之外手术过程中脑室液的释放与病变切除也使得脑室塌陷，轴外间隙扩大。在脑组织的搏动下会有过量的脑脊液由上述通道进入扩大的轴外间隙，并且可将搏动产生的压力传递至脑皮层。最终造成患者颅内压增高出现临床症状。但是此类患者没有脑脊液吸收障碍，轴外间隙与脑室间脑脊液仍有双向循环。理论上可以通过封闭通道来避免此并发症，也有作者进行尝试[13-14]。

本文46例松果区肿瘤患者的手术采用的均为经纵裂胼胝体入路。该入路需分离开放纵裂池劈开胼胝体进入侧脑室显露切除病变。同样造成了一个新的交通通道，使得脑脊液有机会蓄积在轴外间隙。46例患者术后6 h内头部CT均显示有不同程度轴外脑脊液蓄积，但仅有5例出现颅高压症状行手术治疗。新通道越宽阔，脑脊液越容易经此通道至轴外间隙；病变体积越大，术前脑积水越严重则脑组织顺应性越差，术后脑室塌陷也越严重，越难以回位，轴外间隙也越大，越难以消失；新通道下游脑脊液通路越通畅，则脑脊液越容易下行而不向轴外间隙流动，反之亦然。

根据影像学特点对此类患者诊断并不困难。但由于对其具体形成机制不明，因此手术后缺少明确有效的手段阻止该疾病的进展。鉴于治疗的风险，应严格掌握分流手术指征。本研究的5例患者在决定分流手术前都进行了硬膜下穿刺外引流手术，有些患者还在外引流期间进行了硬膜下外引流管夹闭实验。这些都是为了明确分流手术的必要性。只有那些临床症状进行性加重而又没有缓解可能的患者才考虑进行分流手术。我们也有1例患者在严密观察的情况下避免了分流手术。没有证据可以证明硬膜下外引流术可以减少或阻止开颅术后轴外脑脊液蓄积的发生或发展。但在患者出现病情变化时不失为一种快速的急救措施。无论是单侧还是双侧脑脊液蓄积，进行单侧外引流即可缓解症状。

有学者认为硬膜下-腹腔分流手术或脑室-腹腔分流手术对开颅术后轴外脑脊液蓄积都有效。本研究的5例患者中4例都首选硬膜下分流术，这是由于之前都采取了硬膜下外引流手术。这4例患者中有3例因为硬膜下段管梗阻改行侧脑室分流手术。因此在做硬膜下分流时要选择好合适的位置置管，避免脑组织膨复后堵塞分流管[14-17]。

既往文献对开颅术后轴外脑脊液蓄积的报道不多，实际工作中此类并发症可能并不少见。因此熟悉该病症的特点可以减少面对和处理此类疾病时的困惑，使患者及时得到最恰当地处理[18-22]。

参考文献

[1] Eguchi S, Aihara Y, Hori T, et al. Postoperative extra-axial cerebrospinal fluid collection—its pathophysiology and clinical management[J]. Pediatr Neurosurg, 2011, 47(2): 125-132.

[2] Raimondi AJ. A unifying theory for the definition and classification of hydrocephalus[J]. Childs Nerv Syst, 1994, 10(1): 2-12.

[3] Kumar R. External hydrocephalus in small children[J]. Childs Nerv Syst, 2006, 22(10): 1237-1241.

[4] Alvarez LA, Maytal J, Shinnar S. Idiopathic external hydrocephalus: natural history and relationship to benign familial macrocephaly[J]. Pediatrics, 1986, 77(6): 901-907.

[5] Caldarelli M, Di Rocco C, Romani R. Surgical treatment of chronic subdural hygromas in infants and children[J]. Acta Neurochir: Wien, 2002, 144(6): 581-588; discussion 588.

[6] Carolan PL, McLaurin RL, Towbin RB, et al. Benign extra-axial collections of infancy[J]. Pediatr Neurosci, 1985-1986, 12(3): 140-144.

[7] Andersson H, Elfverson J, Svendsen P. External hydrocephalus in infants[J]. Childs Brain, 1984, 11(6): 398-402.

[8] Kendall B, Holland I. Benign communicating hydrocephalus in children[J]. Neuroradiology, 1981, 21(2): 93-96.

[9] Cardoso ER, Schubert R. External hydrocephalus in adults. Report of three cases[J]. J Neurosurg, 1996, 85(6): 1143-1147.

[10] Kawaguchi T, Fujita S, Hosoda K, et al. Treatment of subdural effusion with hydrocephalus after ruptured intracranial aneurysm clipping[J]. Neurosurgery, 1998, 43(5): 1033-1039.

[11] Mizoi K, Takaku A, Suzuki J. Subdural effusion following radical surgery for chiasmal region tumors in children: report of 4 cases[J]. Childs Brain, 1981, 8(4): 307-315.

[12] Tanaka Y, Mizuno M, Kobayashi S, et al. Subdural fluid collection following craniotomy[J]. Surg Neurol, 1987, 27(4): 353-356.

[13] Al-Yamany M, Del Maestro RF. Prevention of subdural fluid collections following transcortical intraventricular and/or paraventricular procedures by using fibrin adhesive[J]. J Neurosurg, 2000, 92(3): 406-412.

[14] Morota N, Sakamoto K, Kobayashi N, et al. Infantile subdural fluid collection: diagnosis and postoperative course[J]. Childs Nerv Syst, 1995, 11(8): 459-466.

[15] Litofsky NS, Raffel C, McComb JG. Management of symptomatic chronic extra-axial fluid collections in pediatric patients[J]. Neurosurgery, 1992, 31(3): 445-450.

[16] Korinth MC, Lippitz B, Mayfrank L, et al. Subdural-atrial and subdural-peritoneal shunting in infants with chronic subdural fluid collections[J]. J Pediatr Surg, 2000, 35(9): 1339-1343.

[17] Nishimura K, Mori K, Sakamoto T, et al. Management of subarachnoid fluid collection in infants based on a long-term follow-up study[J]. Acta Neurochir: Wien, 1996, 138(2): 179-184.

[18] Yoshimoto T, Houkin K, Ishikawa T, et al. Arachnoid membrane closure. Prevention of postoperative cerebrospinal fluid leakage[J]. Surg Neurol, 1999, 52(1): 68-71; discussion 71-2.

[19] Yoshimoto Y, Wakai S, Hamano M. External hydrocephalus after aneurysm surgery: paradoxical response to ventricular shunting[J]. J Neurosurg, 1998, 88(3): 485-489.

[20] Jung TY, Jung S, Jin SG, et al. Prevention of postoperative subdural fluid collections following transcortical transventricular approach[J]. Surg Neurol, 2007, 68(2): 172-176; discussion 176.

[21] Ravid S, Maytal J. External hydrocephalus: a probable cause for subdural hematoma in infancy[J]. Pediatr Neurol, 2003, 28(2): 139-141.

[22] Kurschel S, Ono S, Oi S. Risk reduction of subdural collections following endoscopic third ventriculostomy[J]. Childs Nerv Syst, 2007, 23(5): 521-526.

(本文编辑　郭征)

本文引用：赵杰, 刘景平, 张治平, 李建, 肖格磊, 廖新斌, 金晨. 开颅手术后轴外脑脊液蓄积的治疗体会[J]. 中南大学学报: 医学版, 2015, 40(4): 446-452. DOI:10.11817/j.issn.1672-7347.2015.04.018

Cite this article as: ZHAO Jie, LIU Jingping, ZHANG Zhiping, LI Jian, XIAO Gelei, LIAO Xinbin, JIN Chen. Experience of treatment for accumulation of extra-axil cerebrospinal fluid after skull surgery[J]. Journal of Central South University. Medical Science, 2015, 40(4): 446-452. DOI:10.11817/j.issn.1672-7347.2015.04.018